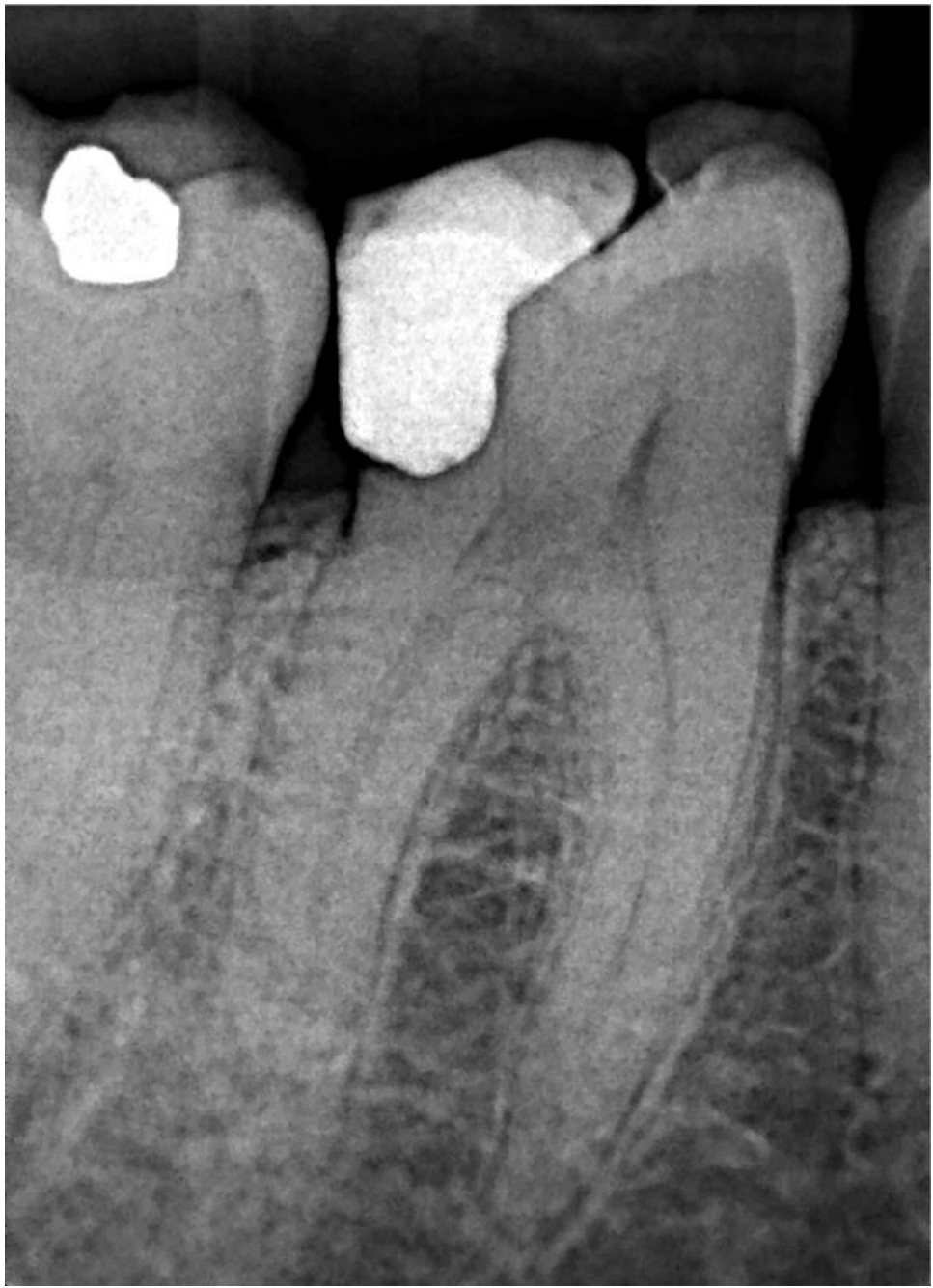
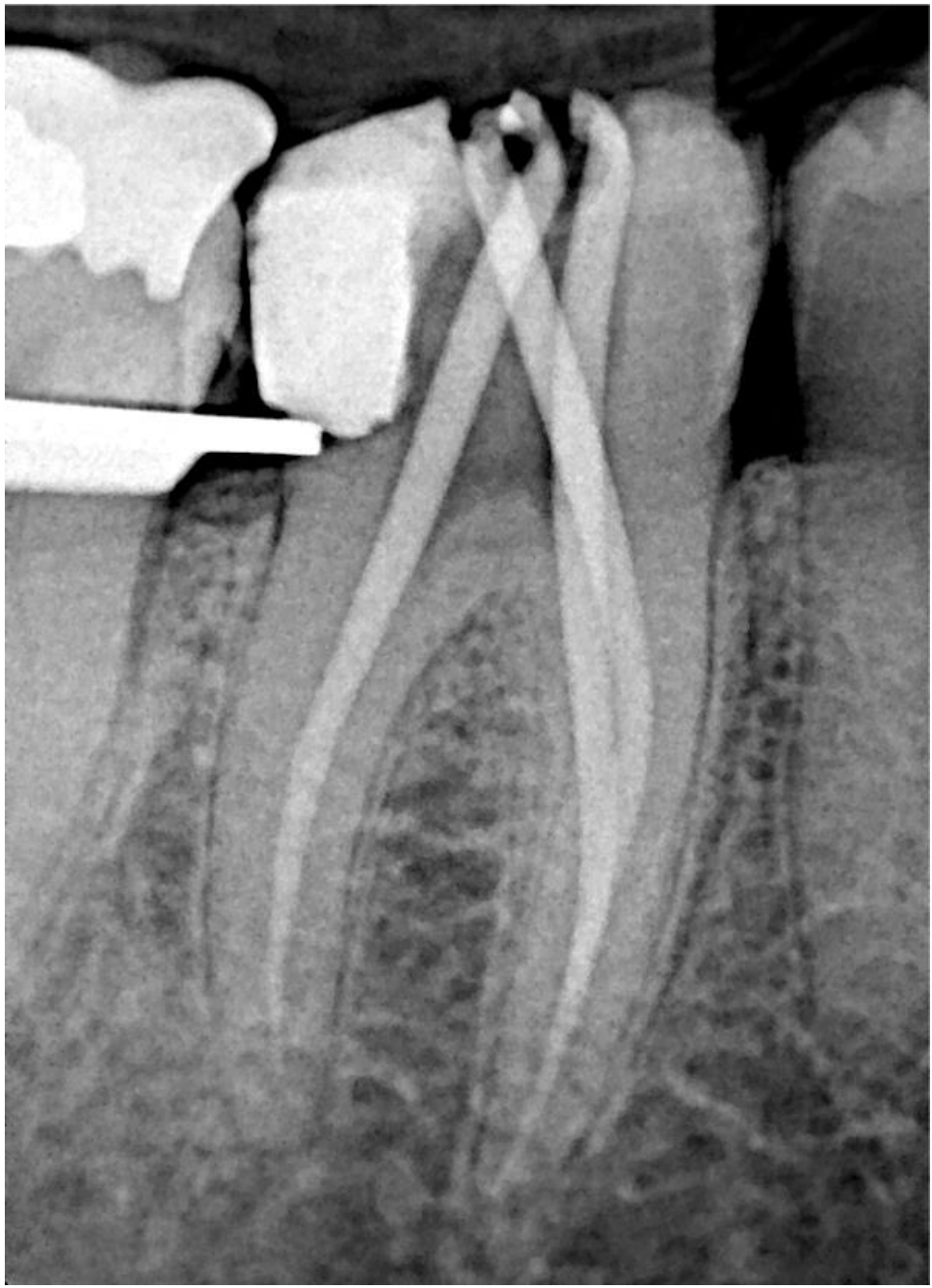


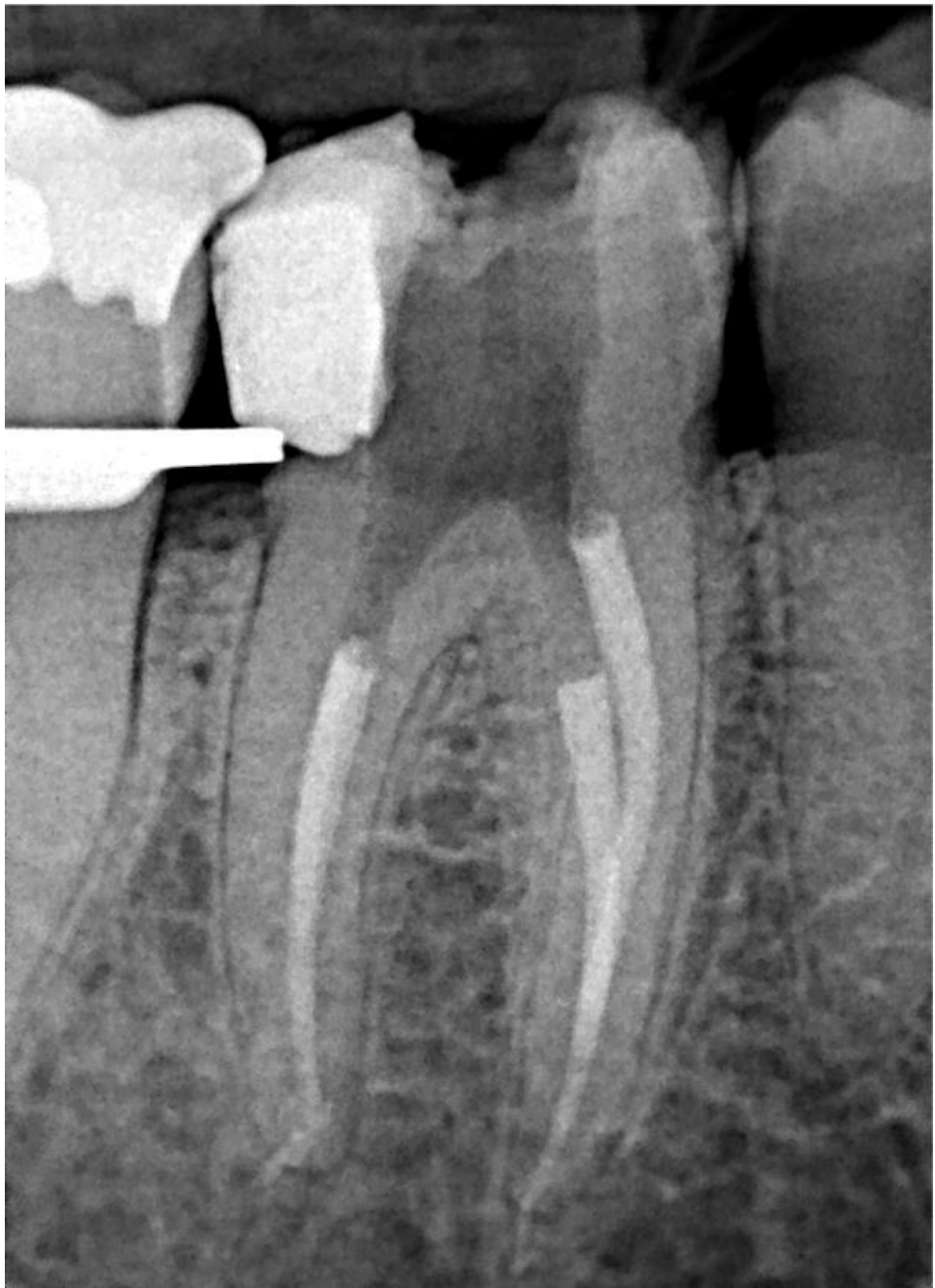
REVERSO BLUE  
DENTE 46  
TRATAMENTO



Radiografia pré-operatória



Radiografia cone-mestre



Radiografia pós-operatória