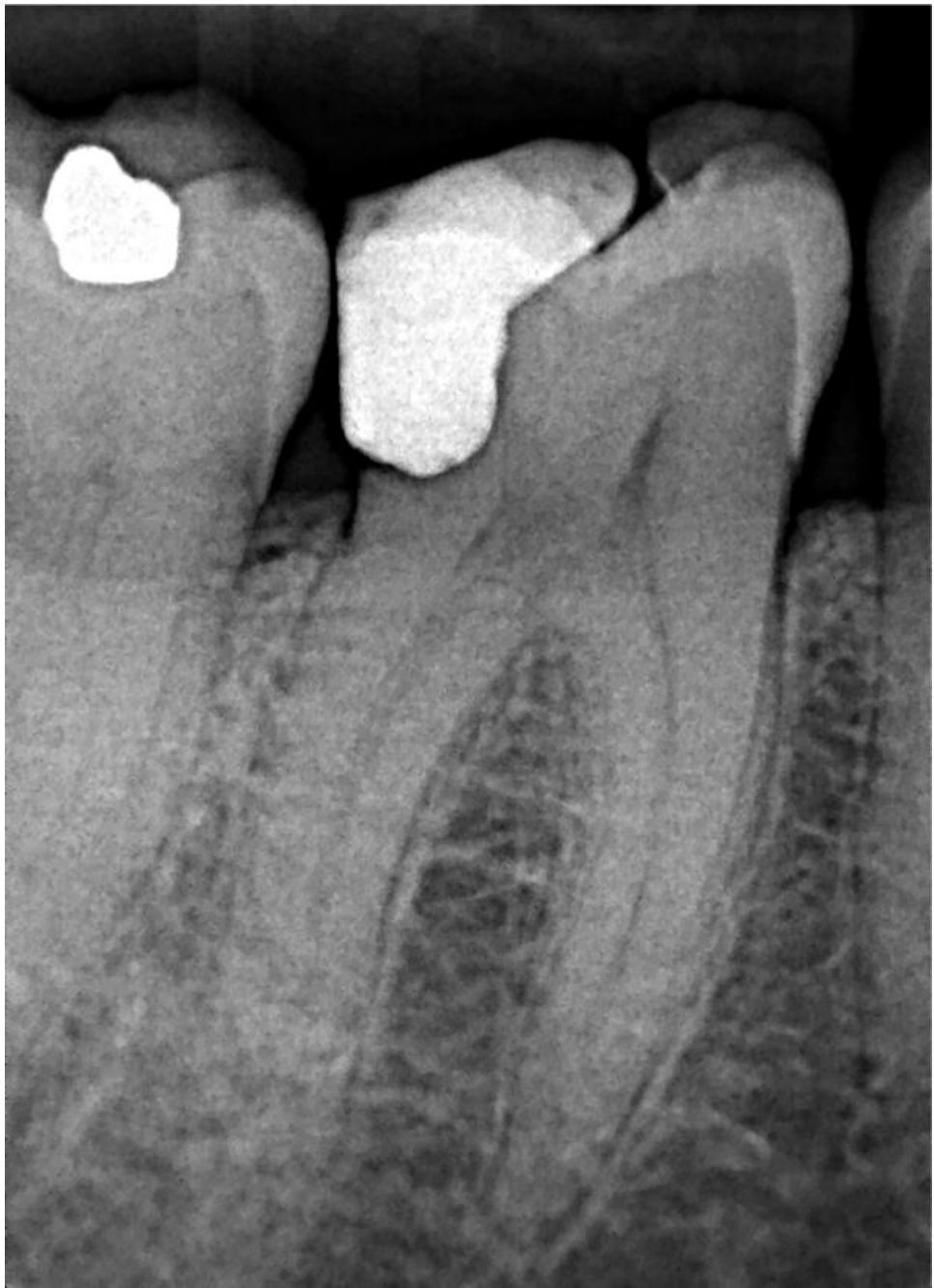
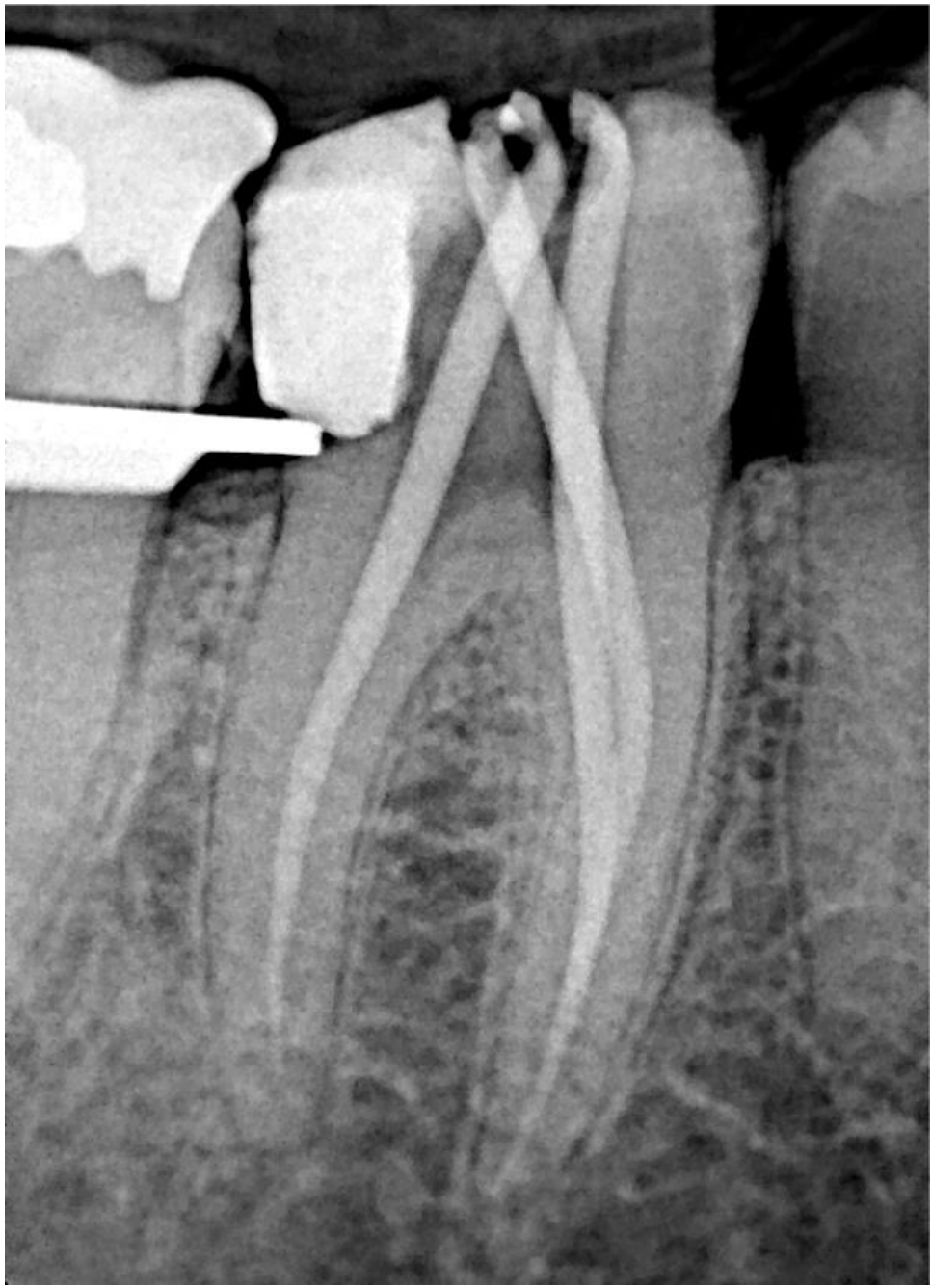


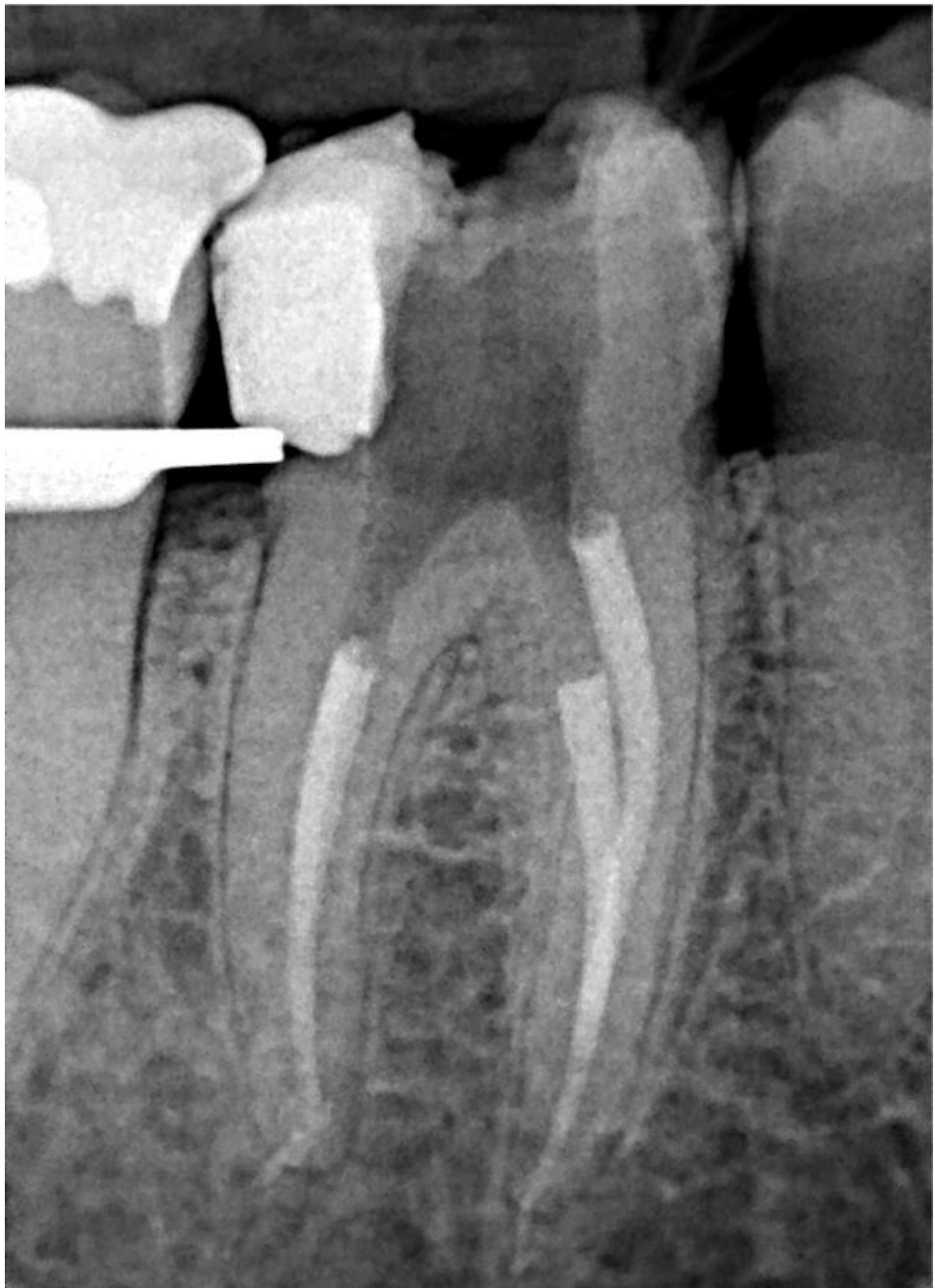
REVERSO BLUE
DENTE 46
TRATAMIENTO



Radiografía preoperatoria



Radiografía de cono maestro



Radiografia postoperatoria